

## Original Research Article

# GROWTH FACTOR CONCENTRATE; LIQUID GOLD FOR ANDROGENETIC ALOPECIA: A RETROSPECTIVE STUDY

Nupur Kapoor<sup>1</sup>, Rahul Yadav<sup>2</sup>

<sup>1</sup>Associate Professor, Oral and Maxillofacial Surgeon, Department of Dentistry, Amaltas Institute of Medical Sciences, Dewas, Madhya Pradesh, India.

<sup>2</sup>Associate Professor and Consultant Plastic Surgeon, Department of Surgery, Amaltas Institute of Medical Sciences, Dewas, Madhya Pradesh, India.

Received : 21/12/2024  
Received in revised form : 12/02/2025  
Accepted : 28/02/2025

### Corresponding Author:

**Dr. Nupur Kapoor,**  
Associate Professor, Oral and Maxillofacial Surgeon, Department of Dentistry, Amaltas Institute of Medical Sciences, Dewas, Madhya Pradesh, India.  
Email: nupur.sagacious@gmail.com

DOI: 10.70034/ijmedph.2025.1.280

Source of Support: Nil.  
Conflict of Interest: None declared

Int J Med Pub Health  
2025; 15 (1); 1493-1497

### ABSTRACT

**Background: Objectives:** To determine the role of growth factor concentrate (GFC) therapy, a modified platelet-rich plasma (PRP) technique for the management of androgenetic alopecia.

**Materials and Methods:** The study includes 15 patients (9 males and 6 females, mean age: 33.06), presenting with the complaint of androgenetic alopecia from December 2023 to June 2024 were treated with subcutaneous injections of GFC in the scalp. A total of 3 injections were administered 4 weeks apart, and the patients were followed up for 24 weeks.

**Results:** The treatment outcomes were assessed by taking global macroscopic photographs, trichoscopic photomicrographs, and by performing a hair pull test after 24 weeks of therapy and compared to the baseline. To determine the safety of the treatment, the incidence of any adverse event was recorded throughout the study period. The patient's self-satisfaction was assessed using a survey-based questionnaire at the end of the study period. The global macroscopic photographs showed a significant improvement in hair growth post-GFC therapy in all 15 patients. These findings were supported by trichoscopic photomicrographs, in which a pronounced improvement in hair density along with a decrease in the shaft diameter variability. Hair pull test was found to be negative in 100% of patients 4 months post-therapy. The therapy was found to be well tolerated with high patient satisfaction (80%).

**Conclusions:** Hence, GFC therapy was found to have a promising role in the management of androgenetic alopecia in both male and female patients.

**Key-words:** Androgenetic alopecia, GFC, Growth factor concentrate, Platelet-rich plasma technique, Global macroscopic photographs, Trichoscopic photomicrographs, Hair pull test.

## INTRODUCTION

There are many different types of alopecia as there are different causes of the condition. Common types are androgenic alopecia, alopecia areata, chemotherapy induced alopecia (CIA), anagen effluvium, telogen effluvium, traction alopecia and trichotillomania. The condition can be classified into two categories; scarring alopecia (instigated by swelling responses to follicle damage) and most common non-scarring alopecia caused by many factors such as hormones, medication, nutrition, and certain illnesses.<sup>[1]</sup>

Androgenic alopecia is common baldness affecting both male (male pattern baldness) and female (female pattern baldness). It affects mostly men as compared to women because men produce more of the causative male sex hormone testosterone. In women, the condition has a different phenotypical expression depicted as scalp hair thinning unlike the hairline recession in men.<sup>[2]</sup> The metabolism of testosterone in the gonads and other parts of the body such as the liver and brain by an enzyme called 5-alpha reductase produces a strong androgen called dihydrotestosterone (DHT). About 10 % of the testosterone produced in the body gets converted

to DHT.<sup>[3]</sup> DHT, also a sex steroid like testosterone, accelerates baldness more compared to other androgens targeting the same receptor sites with a higher binding affinity. The binding of androgens to hair follicle receptors causes progressive shrinkage and weakening of follicles causing destruction of follicle cells. The interface of hair follicle with androgens results in reduced anagen lifespan and prolonged telogen lifespan.

According to Urysiak-Czubatka et al,<sup>[4]</sup> androgenic alopecia affects 70 % of all men and about 40 % of ladies in their entire lifespan. Male individuals who do not develop baldness generally produce less quantities of the 5-alpha reductase enzyme. Androgenic alopecia affects people of Caucasian origin more than other races.<sup>[3,5,6]</sup>

Currently, only two drugs, minoxidil, and finasteride are recognized by the United States (US) Food and Drug Administration as treatments for androgenetic alopecia.<sup>[7]</sup> The drugs must be used regularly for benefits to persist and patients experience a relapse in hair loss when the treatment is halted. Additionally, the prolonged usage of these medications is often accompanied by undesirable side effects like redness and scaling of the scalp, contact dermatitis and hypertrichosis (in women) with minoxidil and reversible loss of libido and erectile dysfunction as well as an incidence of gynecomastia with finasteride.<sup>[8]</sup>

Platelet-rich plasma (PRP) injections have emerged as a promising regenerative therapy for androgenetic alopecia as it possesses minimal chances of side effects, owing to its autologous nature. Recent studies have evidenced a promising role of growth factor concentrate (GFC) therapy, which is a modification of the PRP technique, in hair restoration and treatment for androgenetic alopecia.<sup>[9,10]</sup> However, there is a dearth of studies evaluating the role of GFC therapy in the management of androgenetic alopecia among the Indian population. Therefore, the present study has been conceptualized to determine the potential effect of GFC therapy for the treatment of androgenetic alopecia.

## MATERIALS AND METHODS

### Inclusion Criteria

Patients aged  $\geq 18$  years, diagnosed with androgenic alopecia, and who have not taken any other treatment or any other topical or systemic medication for hair fall in last the 6 months were included in the study.

### Exclusion Criteria

Patients with uncontrolled diabetes mellitus or thyroid dysfunction; anemia, bleeding disorders or platelet disorders; human immuno-deficiency virus (HIV), hepatitis B or C positive or otherwise immunocompromised; history of malignancies; active skin disease or infection at the time of

treatment or with active keloid formation were excluded from the study.

### Procedure

GFC was prepared using the single spin method, 20 ml of blood from each patient was drawn into 4 vacuum blood collection tubes. The contents were gently mixed with the activator, provided in the tube by inverting them 8-10 times and then keeping them upright for 30 minutes, to activate the platelets and release growth factors. The tubes were then centrifuged at 3400 rpm for 10 min, followed by the extraction of GFC from the uppermost layer.<sup>[11]</sup> Before the GFC injection, anaesthesia (lidocaine plus prilocaine) was applied for 40 min to block supraorbital and supratrochlear nerves followed by cleansing with sterile saline.

The collected GFC (about 8-10ml) was injected intradermally using a 30–31gauge needle. About 0.1–0.2 ml of GFC was injected per injection over the affected area of the scalp and injection sites were spaced out from each other by approximately 0.8 to 1 cm. A total of three sessions of GFC therapy were given at 4 weeks apart intervals and follow-up of patients was done till 24 weeks (6 months) for the final clinical assessment.

Study outcomes Hair status was assessed at different follow-up visits (6 weeks after the previous visit till 24 weeks) and compared with the baseline visit (visit-1) with the use of the same hairstyle and photographic position for each patient. The treatment outcomes were assessed by taking global macroscopic photographs, trichoscopic photomicrographs [using a dermatoscope for measuring the hair count], as well as by performing the hair pull test. To perform the hair-pull test, a bundle of 20–60 hairs was gently pulled between the thumb and forefinger from several locations. The test was considered positive if more than 10% of hairs were released.<sup>[12]</sup>

To evaluate the safety of the treatment, the occurrence of any adverse event was recorded along with their severity and relationship to the treatment from baseline to 24 weeks.

Additionally, patients' self-satisfaction was assessed using a survey-based questionnaire at the end of the study period (24 weeks).

## RESULTS

Chief complaints of the patients included receding of hairline, visible baldness, and progressive thinning of hair. The males were observed to have Hamilton-Norwood II, III, VI androgenic alopecia, while females were found to have Ludwig stage I and II alopecia.

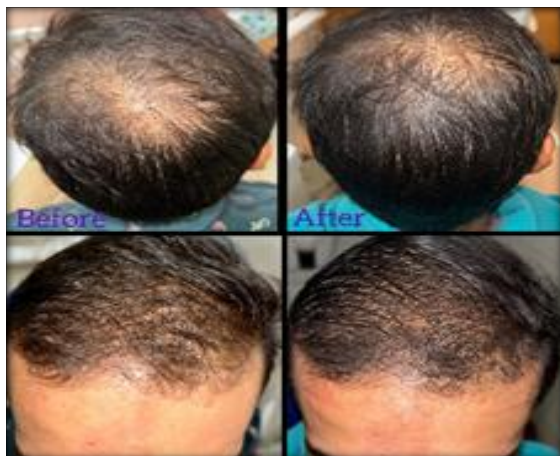Further, topical minoxidil (5%) hair serum and a combination of minoxidil (5%) and finasteride (0.1%) were reported to be used concomitantly in 40.0% and 60.0% of patients, respectively (Table.1). The personal history of patients revealed that 60.0%

of patients had a family history of androgenic alopecia.

**Table 1:**

PATIENTS	SEX	CONCOMITANT MEDICINE USED	ROUTE OF ADMINISTRATION	FAMILIAL HISTORY OF HAIR LOSS	TYPE OF ALOPECIA
1	M	Minoxidil 5% + finasteride 0.1%	Topical	Father	Androgenic alopecia
2	F	Minoxidil 5% hair serum	Topical	None	Not applicable
3	M	Minoxidil 5% + finasteride 0.1%	Topical	Father	Androgenic alopecia
4	M	Minoxidil 5% + finasteride 0.1%	Topical	Father	Androgenic alopecia
5	F	Minoxidil 5% hair serum	Topical	None	Not applicable
6	M	Minoxidil 5% + finasteride 0.1%	Topical	Father	Androgenic alopecia
7	F	Minoxidil 5% hair serum	Topical	None	Not applicable
8	M	Minoxidil 5% + finasteride 0.1%	Topical	Father	Androgenic alopecia
9	M	Minoxidil 5% + finasteride 0.1%	Topical	Father	Androgenic alopecia
10	F	Minoxidil 5% hair serum	Topical	None	Not applicable
11	F	Minoxidil 5% hair serum	Topical	None	Not applicable
12	M	Minoxidil 5% + finasteride 0.1%	Topical	Father	Androgenic alopecia
13	M	Minoxidil 5% + finasteride 0.1%	Topical	Father	Androgenic alopecia
14	F	Minoxidil 5% hair serum	Topical	None	Not applicable
15	M	Minoxidil 5% + finasteride 0.1%	Topical	Father	Androgenic alopecia

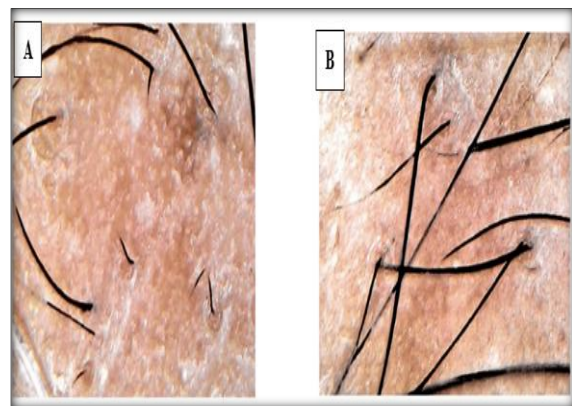
**Effectiveness:** On comparing the global macroscopic photographs taken before and after 24 weeks of treatment, GFC therapy was observed to markedly improve the hair appearances in all the patients. The hair photomicrographs showed an evident regrowth of hair in the balding area and improved hair density after 24 weeks of GFC therapy as compared to the baseline. Figure 1 are case representatives of the effectiveness of GFC therapy in restoring hair growth after three sessions of therapy.



**Figure 1:** shows the before and after picture of the patients

Further, the observations of trichoscopy images also demonstrated a pronounced improvement in hair density along with a decrease in the shaft diameter variability and number of yellow dots after 24 weeks of GFC therapy as compared to the baseline in all

the patients. One such example is illustrated in Figure 2, wherein the terminal hair ratio was observed to be markedly increased after 24 weeks post-treatment compared to the baseline.



**Figure 2:** Trichoscopic image of a patient (a) before treatment, and (b) 24 weeks after treatment

Data were presented as mean and standard deviation and compared using paired t test. Statistical significance was considered at p value <0.05.

Hair-pull test, which was found to be positive in 60.0% (9 out of 15) of patients at baseline, implying active hair shedding; was observed to be negative in 100% of these patients after 4 months of treatment, indicating hair restoration in all the patients' post-GFC therapy. Safety All adverse events reported by the patients were mild such as scalp pain at the injection site (mild in 88% and moderate in 12% of patients), erythema (55%), and scalp irritation during the healing process (30%). However, all these adverse events were reported to

be resolved spontaneously within a few hours to a few days of onset. Patients' satisfaction in the survey-based questionnaire, used to determine patients' self-satisfaction, when asked about whether their bald spot is getting smaller, most of them (80%) strongly agreed. When questioned about the improvement in hair growth after therapy, 80% of the patients reported a moderate increase in hair growth. Further, the patients were inquired about the effectiveness of the treatment in slowing down their hair loss, 75% of the patients perceived it to be very effective. Regarding self-satisfaction about the treatment, 80% of patients reported being very satisfied. Lastly, patients' self-satisfaction score was evaluated using a Likert scale (1=very unsatisfied, 2=unsatisfied, 3=indifferent, 4=satisfied, or 5=very satisfied), to which most patients (80%) scored 5, indicating that they were very satisfied with the GFC therapy.

## DISCUSSIONS

Hair loss, especially AGA, is a prevalent issue that affects both men and women. Numerous factors contribute to this condition, including heightened stress levels, hormonal imbalances, genetic conditions, and deficiencies in various essential nutrients.<sup>[13]</sup>

Various treatment options have been proposed to address androgenic alopecia, including the use of growth concentrates, platelet-rich plasma, and other growth factors.

In recent years, there has been growing interest in these treatments due to their potential to stimulate hair growth and improve hair density. This interest has been fuelled by studies such as that of Dhurat et al,<sup>[14]</sup> which demonstrated the efficacy of micro-needling in conjunction with platelet-rich plasma in treating AGA. Other studies, as done by Kim et al,<sup>[15]</sup> and Khatu et al,<sup>[16]</sup> have scrutinized the use of platelet-rich plasma and GFC, respectively, as standalone treatments for AGA.

Moreover, Fertig and Gamret,<sup>[17]</sup> have reviewed the current evidence for the use of platelet-rich plasma and growth factors in treating AGA. These studies highlight the potential benefits of GFC and other growth factor treatments in addressing hair loss and provide a basis for further research in this area.

The current conventional treatment approach primarily involves the use of oral or topical medications. However, these treatments necessitate long-term medication usage, and their effectiveness is often hindered by challenges related to patient adherence and the frequent occurrence of side effects.

Surgical interventions, such as hair transplantation, are typically reserved for patients who have areas with no hair follicles.

The GFC treatment involves the precise injection of a person's own growth factors (e.g. epidermal growth factor vascular, endothelial growth factor,

platelet-derived growth factor, and insulin-like growth factor 1) directly into the scalp.

These growth factors act on the hair follicle stem cells, thus promoting neovascularization and the growth of new follicles. PDGF forms the hair canal, VEGF promotes angiogenesis, EGF promotes the proliferation of the hair shaft and aids hair growth, and IGF-1 promotes follicular growth.<sup>[19]</sup>

This targeted delivery at the hair root promotes the stimulation of hair regrowth by providing these growth factors in a concentrated form. Blood platelets are enriched with various growth factors. Scientists extract them from the blood at a high concentration using a specially designed GFC kit. Specialists then administer the collected GFC with precise tools. The overall process involves no platelet loss. It is nonpyrogenous and secure, and it regenerates damaged tissues naturally. This advanced hair loss treatment helps a person achieve optimal results in only three to four sittings. Therefore, it is the best procedure to restore lost hair.

## CONCLUSION

The use of GFC and platelet-rich plasma has shown promising results and may be considered a treatment option for AGA. Studies have demonstrated the potential efficacy of these treatments in stimulating hair growth and improving hair density in AGA patients. The mechanisms underlying these effects are not fully understood but may involve the promotion of angiogenesis and the release of growth factors that promote hair growth. GFC helps in the reduction of hair loss, improves hair thickness, and enhances hair volume.

Although further research is needed to establish the efficacy and safety of these treatments, the current evidence suggests they may be a viable option for people looking to address hair loss. Overall, the use of GFC in treating hair loss is a potential area of research that may provide patients with a safe and effective option for addressing this common concern.

## REFERENCES

1. Hardlife Rambwawasvika. Alopecia types, current and future treatment, January 2021, Journal of Dermatology & Cosmetology 5(4):93-99
2. Semalty M, Semalty A, Joshi GP, et al. Hair growth and rejuvenation: an overview. Journal of Dermatological Treatment. 2011; 22(3):123-132.
3. Dhariwala MY, Ravikumar P. An overview of herbal alternatives in androgenetic alopecia. Journal of cosmetic dermatology. 2019; 18(4):966-975.
4. Urysiak-Czubatka I, Kmieć ML, Broniarczyk-Dyła G et al. Assessment of the usefulness of dihydrotestosterone in the diagnostics of patients with androgenetic alopecia. Postępy Dermatologii i Alergologii. 2014;31(4):207-215.
5. Kelly Y, Blanco A, Tosti A et al. Androgenetic alopecia: an update of treatment options. Drugs. 2016;76(14):1349-1364.
6. Kaliyadan F, Nambiar A, Vijayaraghavan S, et al. Androgenetic alopecia: an update. Indian journal of dermatology, venereology and leprology. 2013;79(5):613.



7. Mulugeta M, Wang L, Taché Y, et al. Salk Institute for Biological Studies, assignee. Methods for promoting hair growth. United States patent US. 10,166,271. 2019.
8. Keum DI, Pi LQ, Hwang ST, et al. Protective effect of Korean Red Ginseng against chemotherapeutic drug-induced premature catagen development assessed with human hair follicle organ culture model. *Journal of ginseng research*. 2016;40(2):169–175.
9. Geyfman M, Plikus MV, Treffeisen E, et al. Resting no more: re-defining telogen, the maintenance stage of the hair growth cycle. *Biological Reviews*. 2015;90(4):1179–1196.
10. Orasan MS, Roman II, Coneac A, et al. Hair loss and regeneration performed on animal models. *Clujul Medical*. 2016;89(3):327–334.
11. Growth factor concentrate therapy for management of hair loss: a prospective, real-world study Namrata Singh<sup>1</sup>, Mamatha Reddy<sup>2</sup>, Gouthami Jajapuram *International Journal of Research in Dermatology* | January-February 2023 | Vol 9 | Issue 1
12. Xu L, Liu KX, Senna MM. A Practical Approach to the Diagnosis and Management of Hair Loss in Children and Adolescents. *Front Med (Lausanne)*. 2017;4:112.
13. Gkini MA, Kouskoulis AE, Tripsianis G, Rigopoulos D, Kouskoulis K: Study of platelet-rich plasma injections in the treatment of androgenetic alopecia through an one-year period. *J Cutan Aesthet Surg*.2014, 7:213-9. 10.4103/0974-2077.150743
14. Dhurat R, Sukesh M, Avhad G, Dandale A, Pal A, Pund P: A randomized evaluator blinded study of effect of microneedling in androgenetic alopecia. A pilot study. *Int J Trichology*. 2013, 5:6-11. 10.4103/0974-7753.114700
15. Kim DH, Jeong KH, Park HJ: Effect of platelet-rich plasma and concentrated growth factors on hair growth in male pattern baldness: a randomized double-blind placebo-controlled pilot study. *J Cosmet Laser Ther*.2018, 20:327-32.
16. Khatu SS, More YE, Gokhale NR, Chavhan DC, Bendsure N: Platelet-rich plasma in androgenic alopecia: myth or an effective tool. *J Cutan Aesthet Surg*. 2014, 7:107-10. 10.4103/0974-2077.138352
17. Fertig RM, Gamret AC: The use of platelet-rich plasma and growth factors in the treatment of androgenetic alopecia. *J Cosmet Dermatol*. 2019, 18:728-33.
18. Steward EN, Patel H, Pandya H, Dewan H, Bhavsar B, Shah U, Dholakia K: Efficacy of platelet-rich plasma and concentrated growth factor in treating androgenetic alopecia - a retrospective study. *Ann Maxillofac Surg*. 2020, 10:409-16. 10.4103/ams.ams\_154\_19
19. Zhao F, Hao L, Jin X: Clinical observation and evaluation of CGF in the treatment of androgenic alopecia . *J cosmet Dermatol*. 2022, 21:5723-9. 10.1111/jocd.15109.